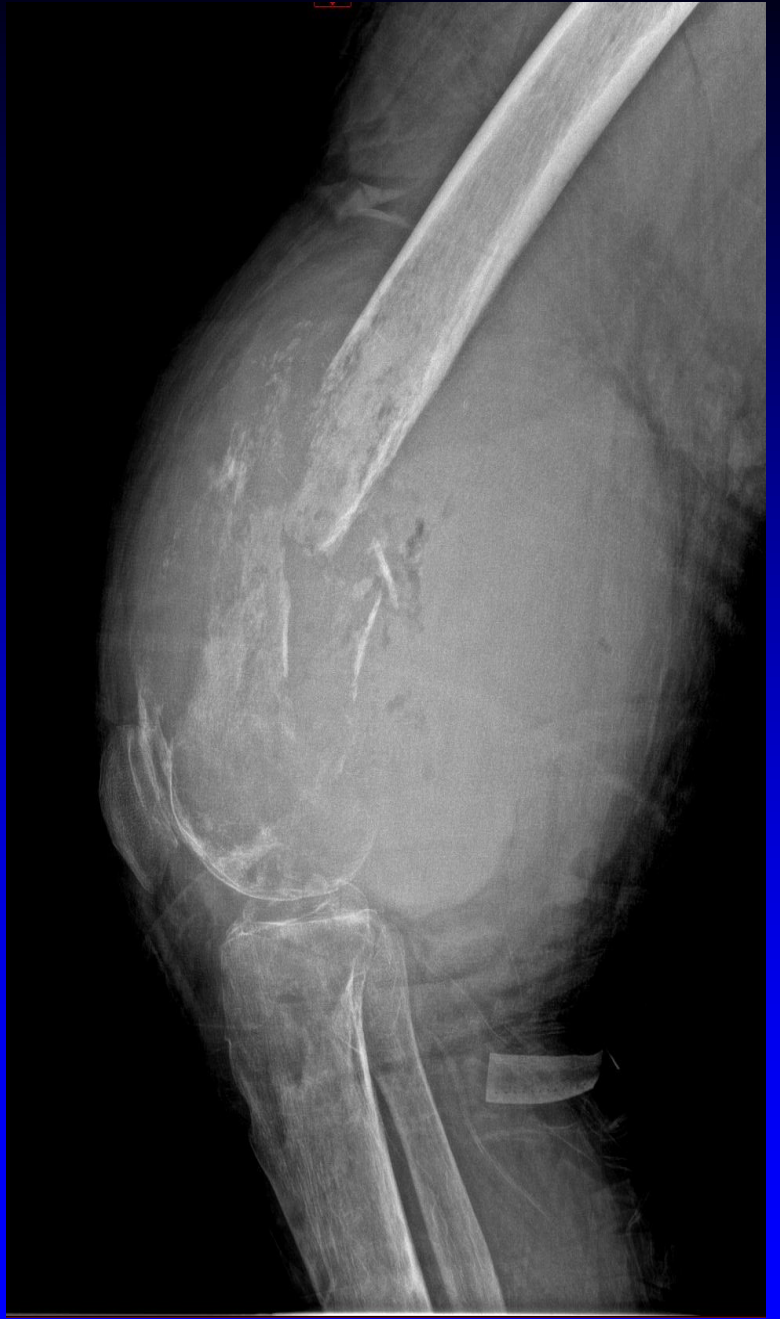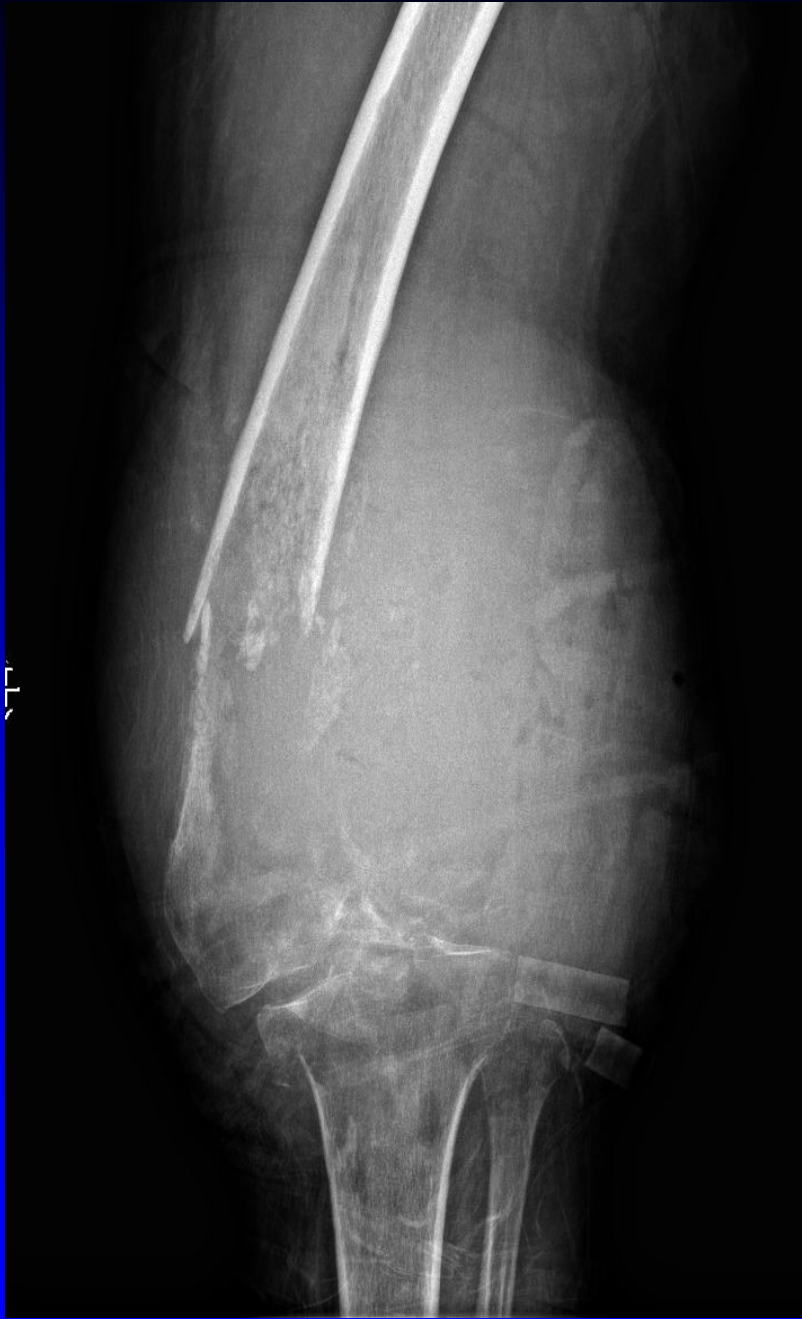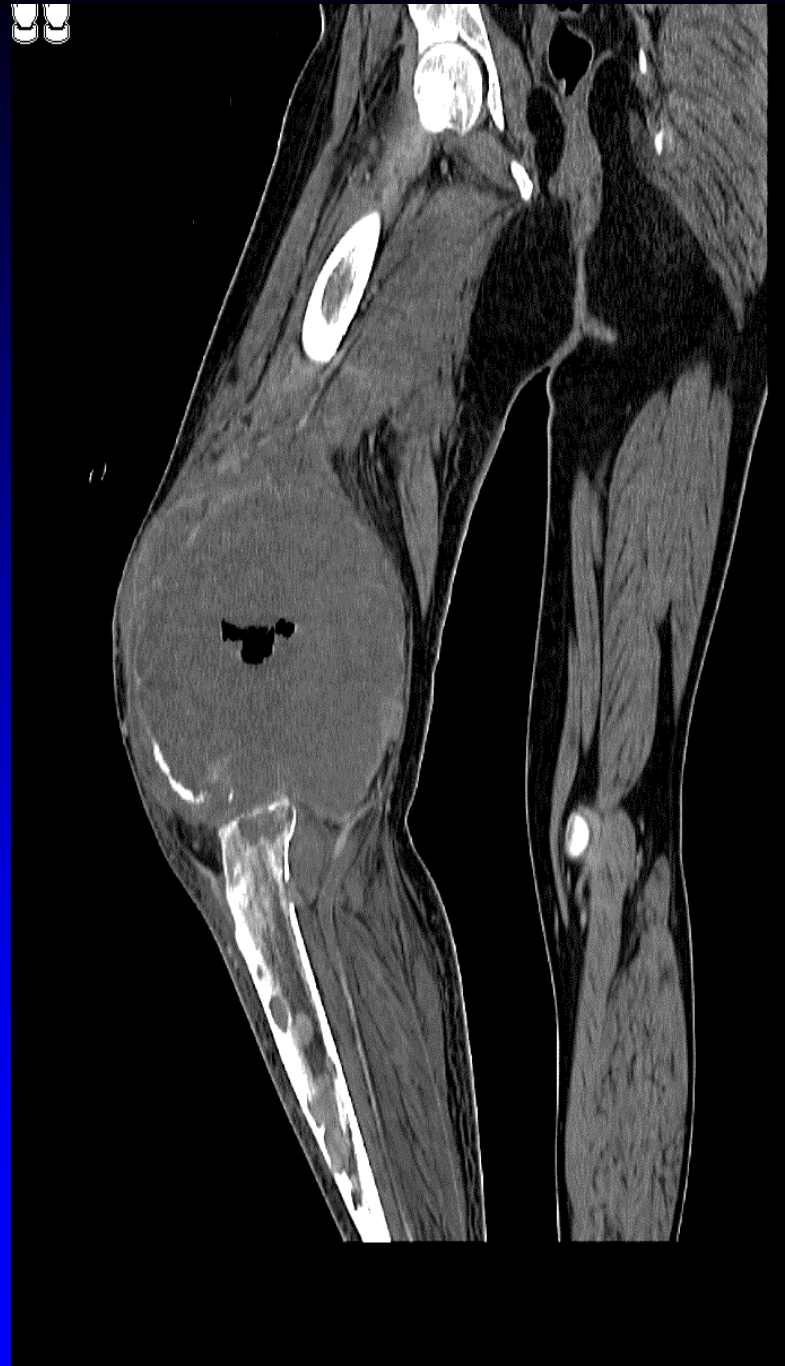
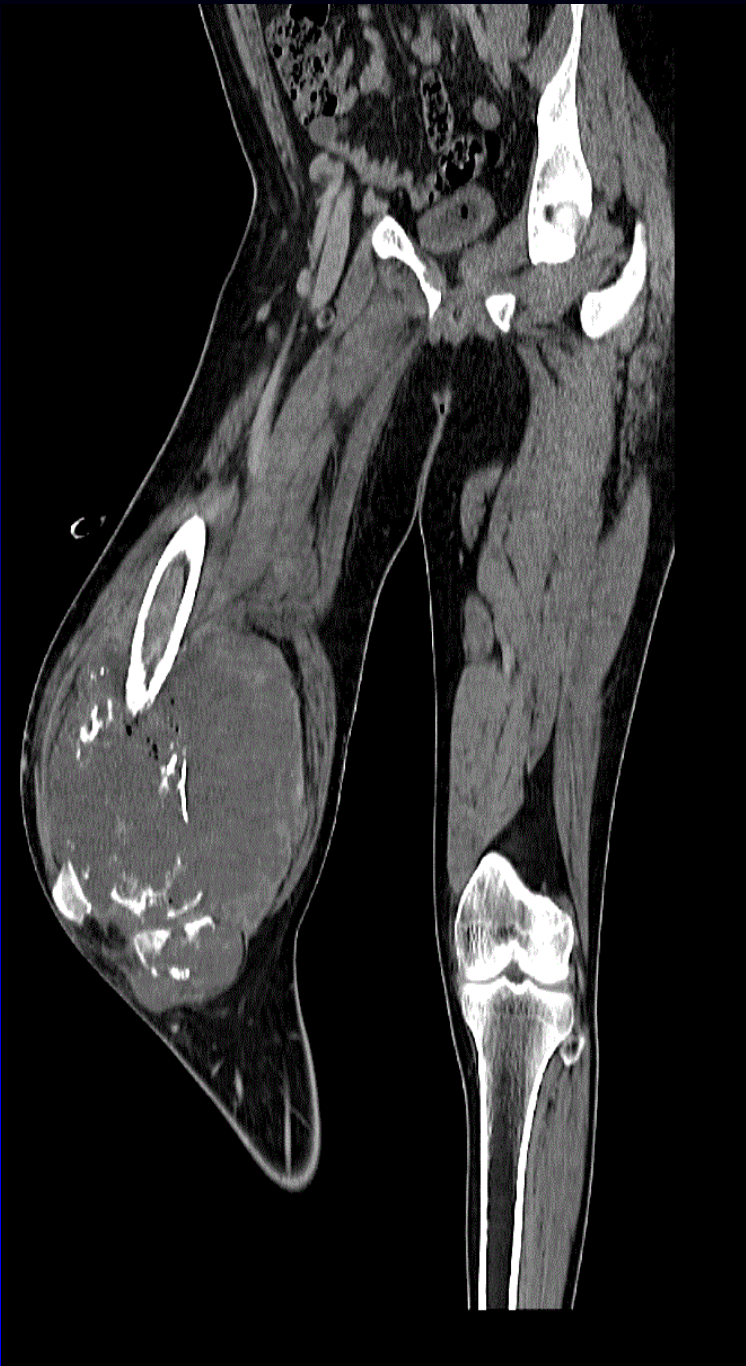
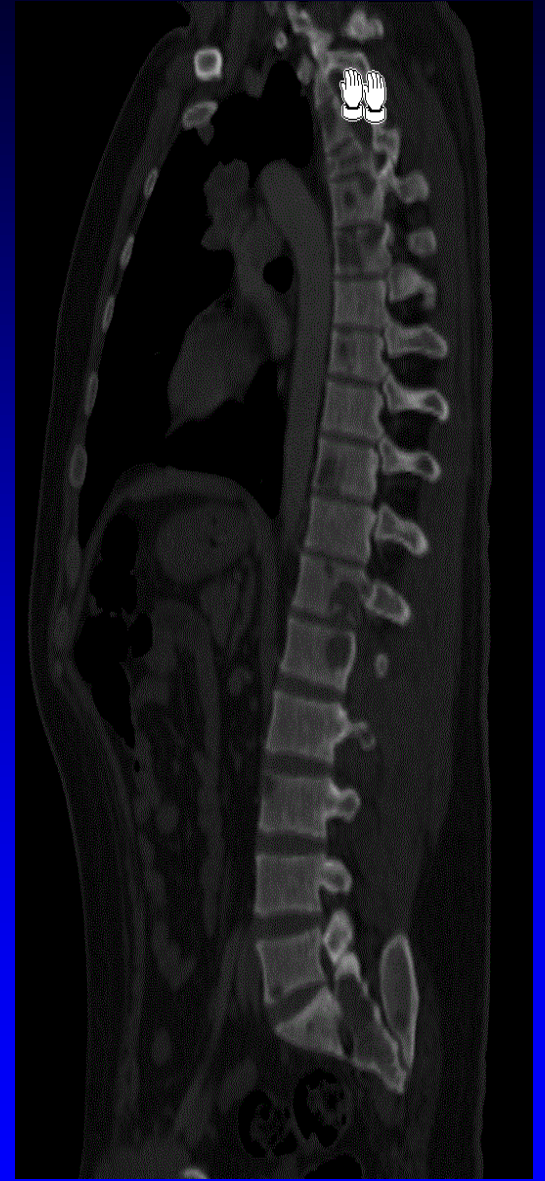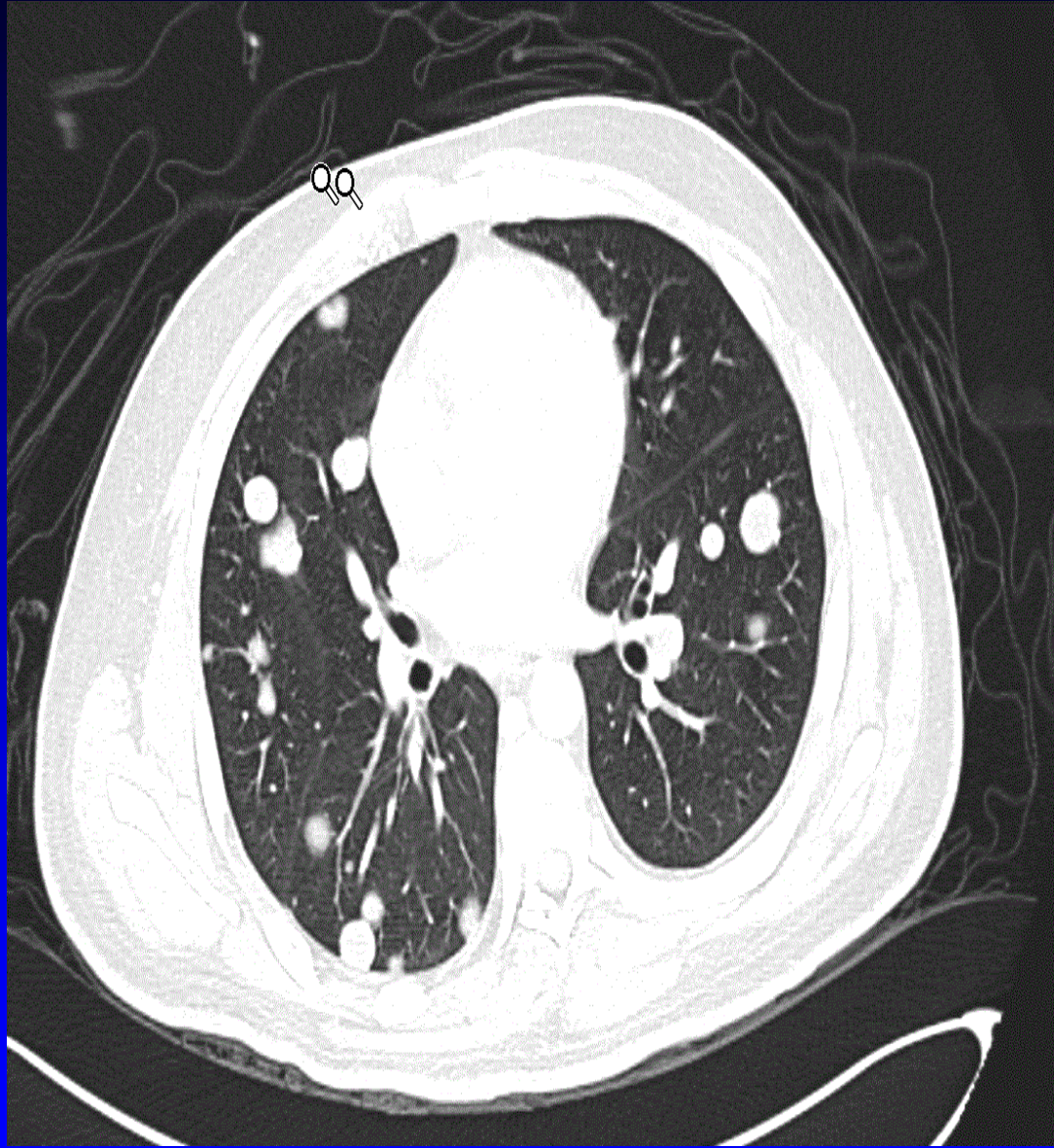


CASO CLINICO

- Hombre de 35 años.
- Lesión en fémur distal.







27-06-13



