



Slide Seminar

DR. ISABEL ALVARADO_CABRERO
Chief of the Department of Pathology
Mexican Oncology Hospital
IMSS, MEXICO
keme2.tijax12@gmail.com

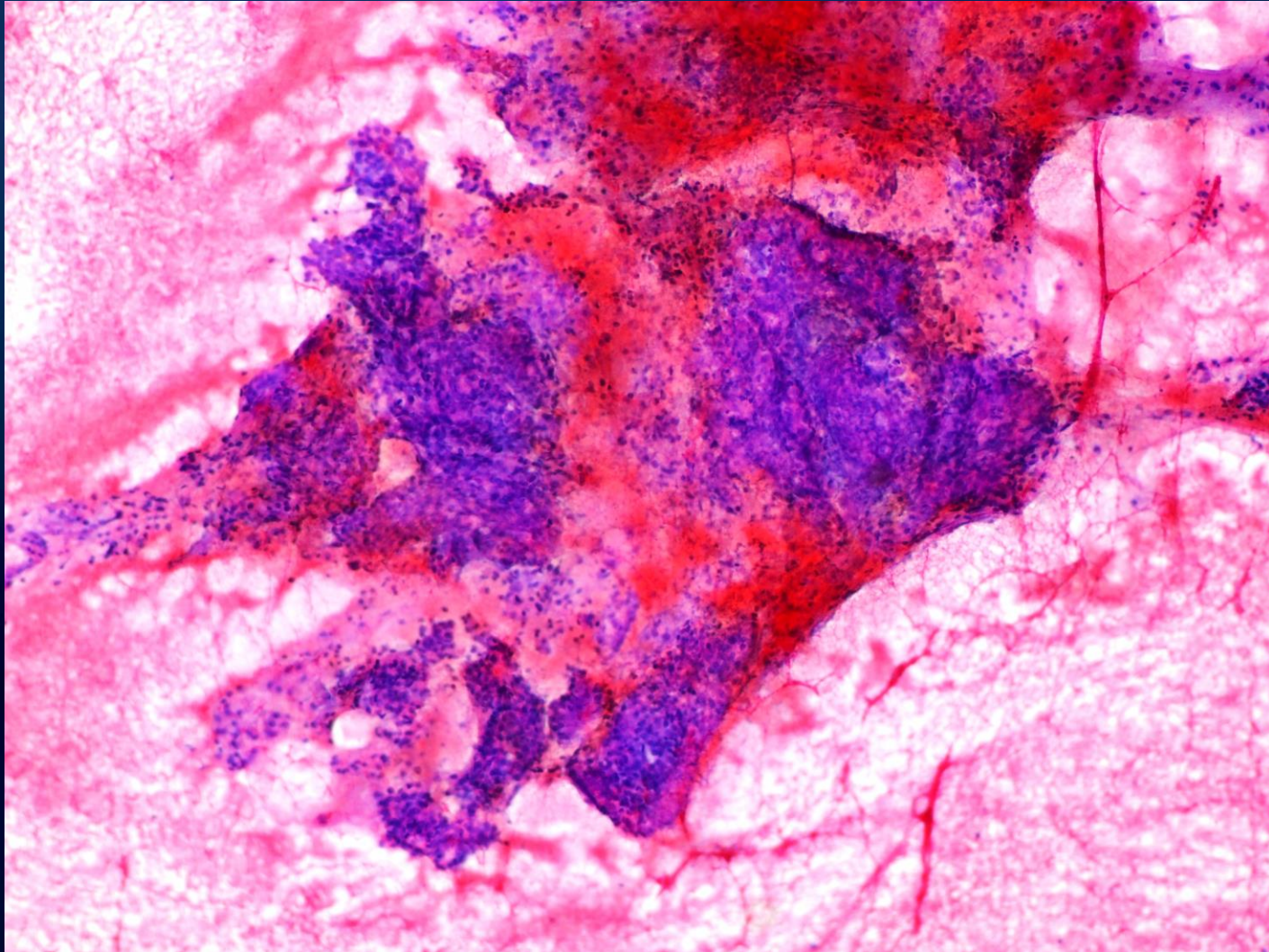
Patient History

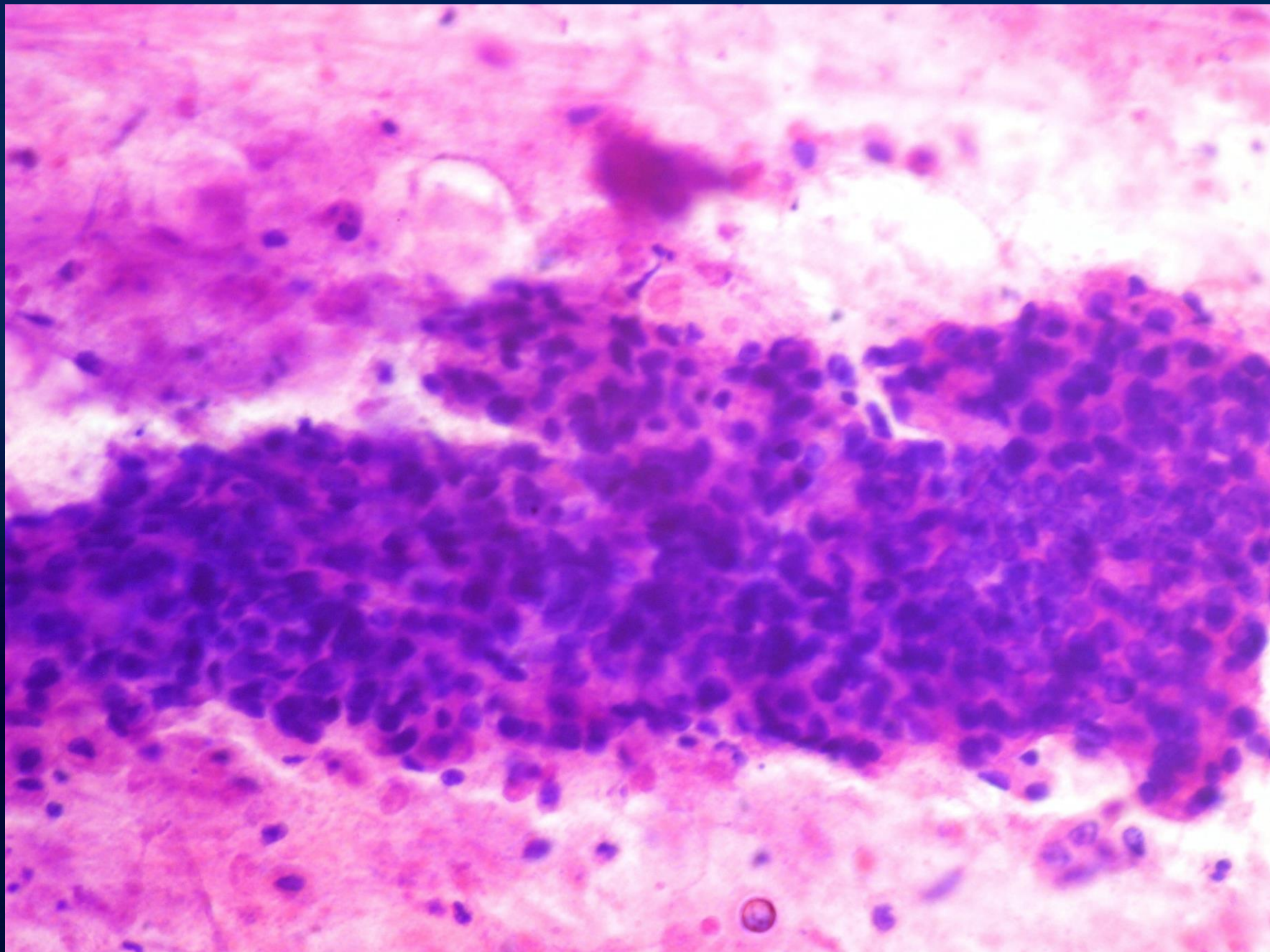
- 69-yr-old woman
- Gravida 4, para 4
- No previous Pap smear
- Complaints:
 - Abdominal pain
 - Dysuria
- Gynecologic examination:
 - Cervical polypoid tumor

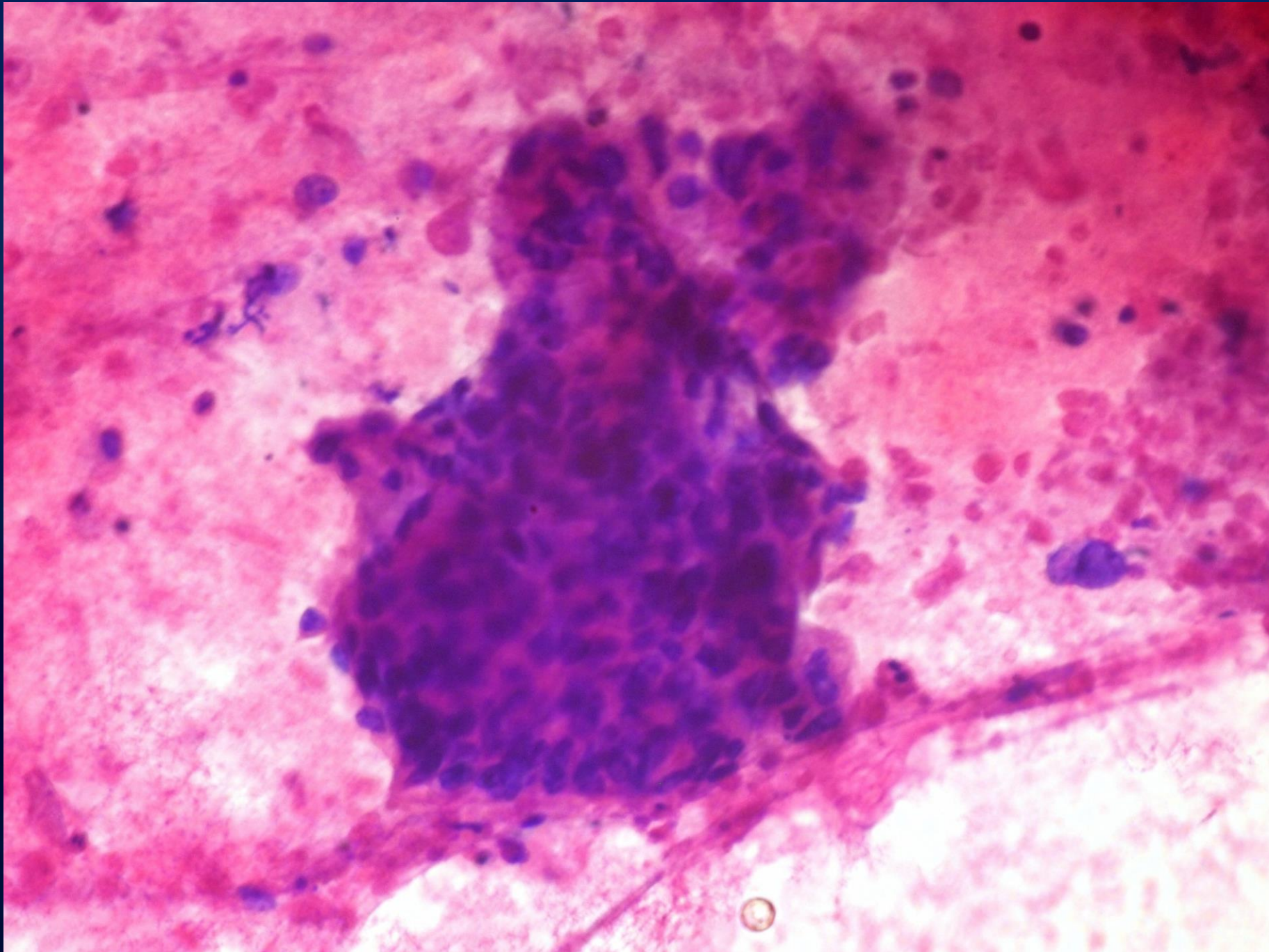
Patient History

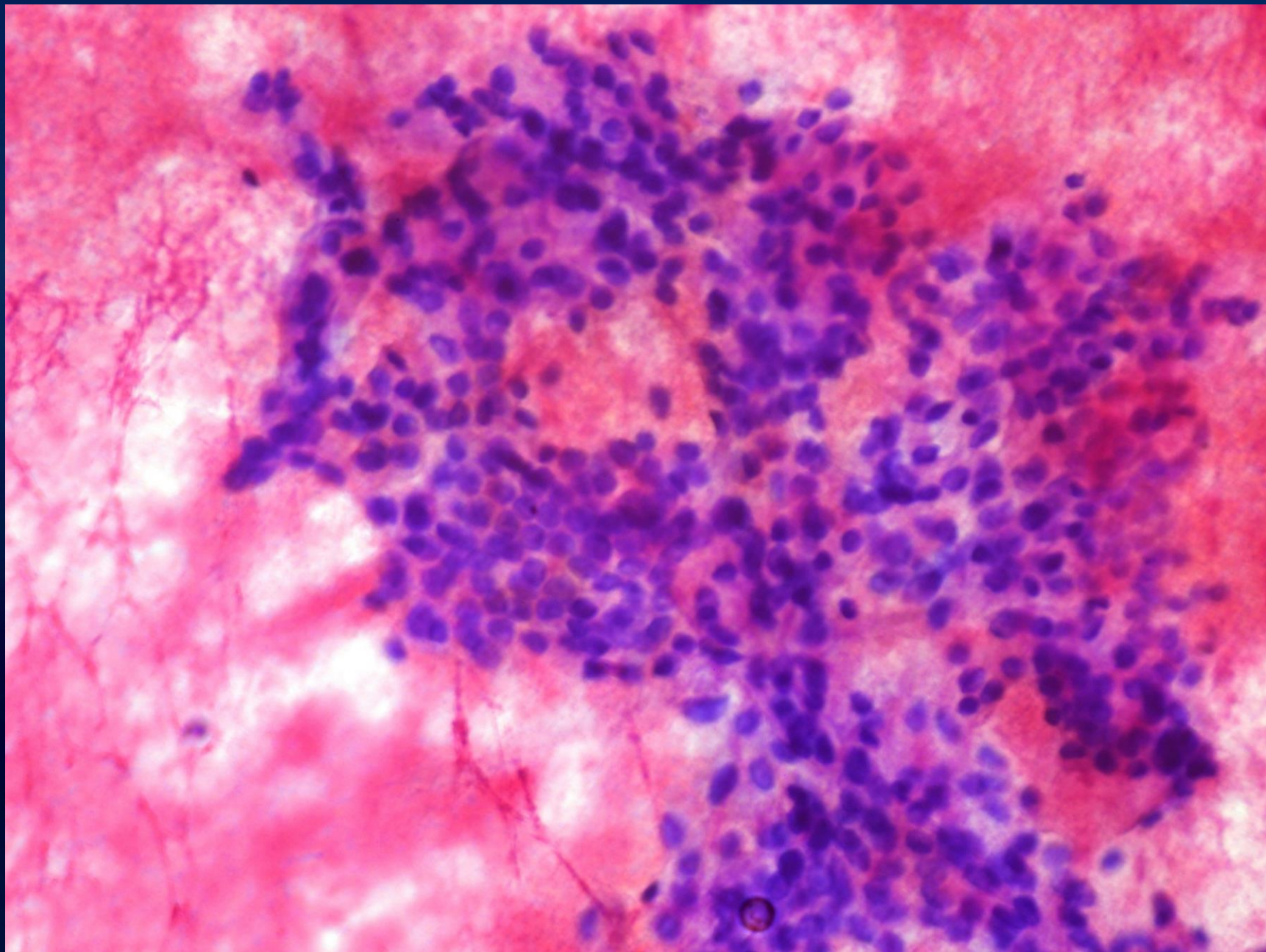
- Pelvic MRI:
 - Tumor of the uterine cervix: 3.7x3.6 cm
- Pap smear and cervical biopsy led to a diagnosis of malignancy
- Tumor stage was Ib1
- Patient underwent:
 - Radical hysterectomy with bilateral pelvic lymphadenectomy

Conventional Pap Smear









Which is your diagnosis?

- a) High Grade Squamous Intraepithelial Lesion
- b) Squamous Cell Carcinoma
- c) Small Cell Neuroendocrine Carcinoma
- d) Poorly Differentiated Squamous Cell Carcinoma